Portal Vein Thrombosis

Understanding a Critical Vascular Condition

Prof. Farhad Zamani

Professor of Gastroenterology and Hepatology

GILDRC- IUMS

September 2025- IAGH

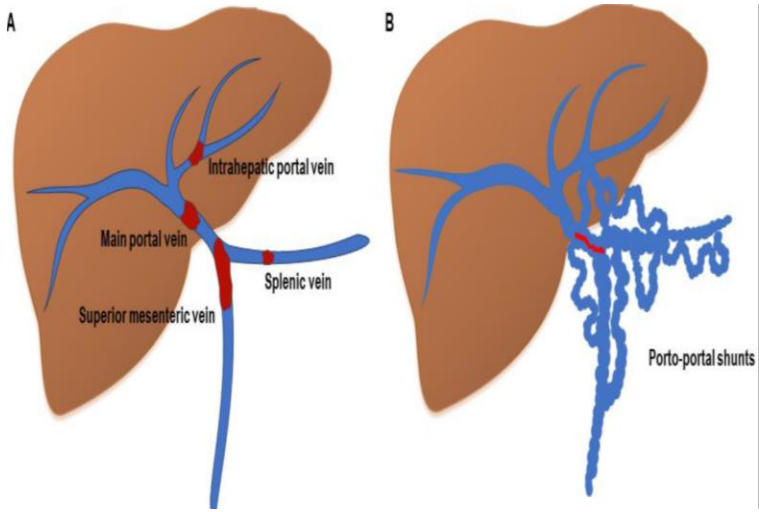

PVT definition:

- ✓PV is formed by the confluence of splenic vein and superior mesenteric vein (SMV) , draining the spleen and small intestine, respectively.

- ✓Thrombosis may limited in the PV or extend to the SMV or splenic vein

- ✓Complications can include portal hypertension, a cavernous transformation , varices, septic thrombosis, or intestinal ischemia

J. Clin. Med. 2024, 13, 1517

Presentation :

- Portal vein thrombosis is asymptomatic in a majority of patients.
- Clinically, PVT may be acute or chronic
- The presentation is dependent upon the extent and rate of thrombus formation
- The presentation of acute PVT can range from abdominal pain to intestinal ischemia/infarction and even death
- Chronic PVT can remain clinically silent.

Symptoms and Clinical Presentation

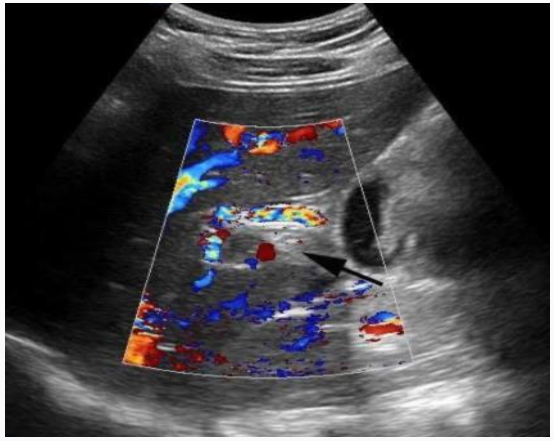



Acute PVT(recent ,<30 days) can present range from abdominal pain to death

Chronic PVT can remain clinically silent.

When symptoms appear, they may include:

- Acute abdominal pain (particularly in the upper right quadrant)
- Enlarged spleen (splenomegaly)
- Hematemesis (vomiting blood) and melena (dark, tarry stools)
- Ascites (fluid accumulation in the abdomen)
- Fever and signs of infection in cases related to abdominal inflammation

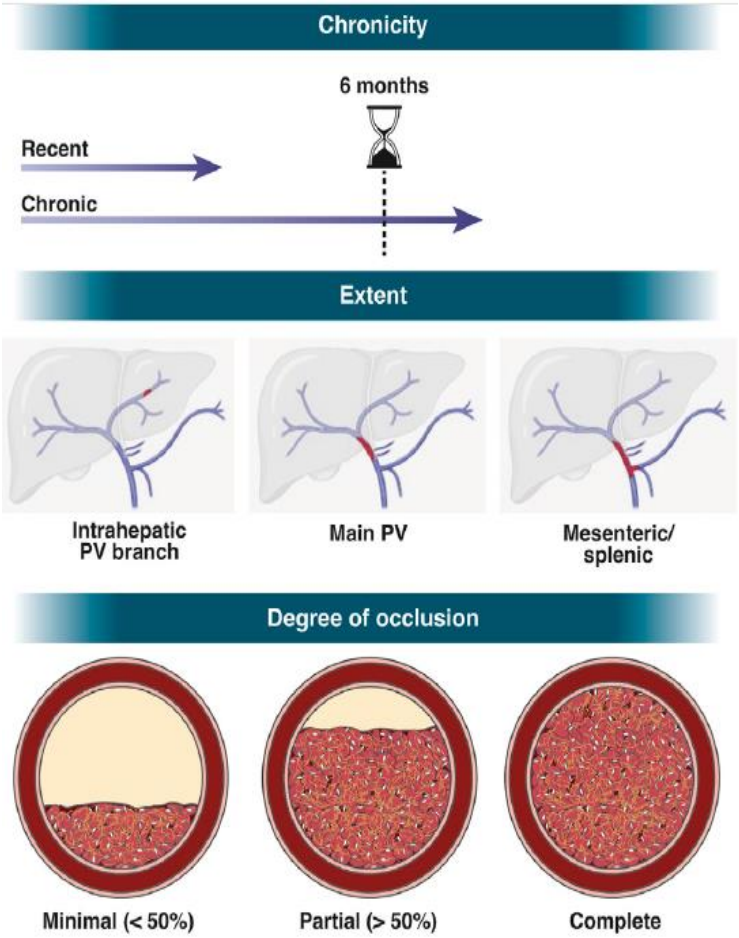

When you suspect PVT?

commonly seen in people with predisposing conditions :

- ✓ Cirrhosis
- ✓ Hepatobiliary malignancies
- ✓ Infectious
- ✓ Inflammatory abdominal disease
- ✓ Haematologic disorders

Gastroenterology 2025;168:396–404: AGA recommendation

Who is at Risk?

Key Causes and Predisposing Factors



Cirrhosis

The most common cause, slowing blood flow and increasing clot risk. **Up to 25% of cirrhotic patients develop PVT**.



Abdominal Infections

Appendicitis, diverticulitis, and pancreatitis can trigger inflammatory responses leading to blood clot formation. formation.



Malignancies

Cancers of the liver, pancreas, and digestive system can compress or invade the portal vein.



Clotting Disorders

Genetic mutations (e.g., JAK2), pregnancy, and hereditary hereditary thrombophilias increase clotting risk.

Risk factors for non-cirrhotic non-malignant portal vein thrombosis

Risk factor	Prevalence	Investigations
Systemic		
Myeloproliferative neoplasm	21-32	JAK2 V617F mutation testing CALR mutation testing if platelets > 200 × 10^9/L and spleen ≥ 16 cm Consider bone marrow biopsy
Acquired thrombophilia		
Antiphospholipid syndrome	6	Lupus anticoagulant, anti-cardiolipin and anti-b2 glycoprotein-I antibodies (2 positive samples 12 wk apart)
Paroxysmal nocturnal haemoglobinuria	0.30	Flow cytometry (CD55 and CD59 deficient cells)
Inherited thrombophilia		
Prothrombin G20210A gene mutation	6-7	Prothrombin G20210A mutation testing
Factor V Leiden	3-7	Factor V Leiden mutation testing
Protein C deficiency	5-6	Protein C levels[1]
Protein S deficiency	3-5	Protein S levels[1]
Antithrombin deficiency	1-4	Antithrombin levels[1]
Hormonal (recent pregnancy/oral contraceptive)	16	Medical history
Other systemic disease *e.g.*, connective tissue disease, sarcoidosis, vasculitis, acute CMV infection	3	Variable
Obesity		Medical history
Local		
Abdominal trauma/surgery	14	Medical history/cross-sectional imaging
Inflammatory abdominal conditions *e.g.*, pancreatitis, biliary infection, appendicitis, inflammatory bowel disease	11	Variable
No cause identified	35-42	

World J Hepatol 2024 May 27; 16(5): 751-765

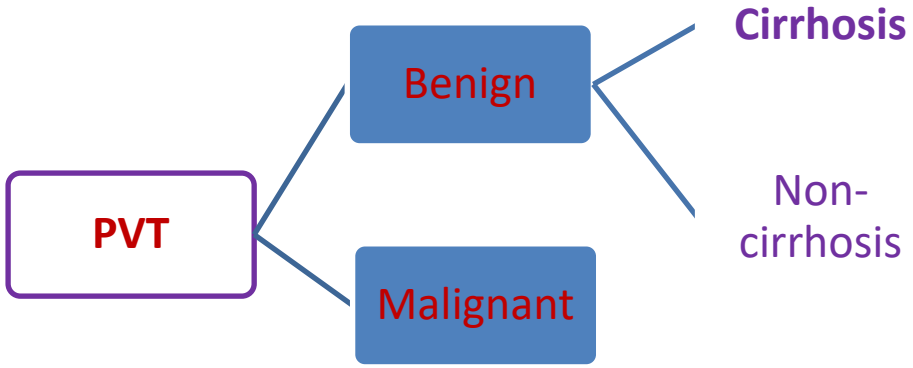



PVT complications can include

- Portal hypertension
- cavernous transformation of the portal vein
- varices
- septic thrombosis
- intestinal ischemia

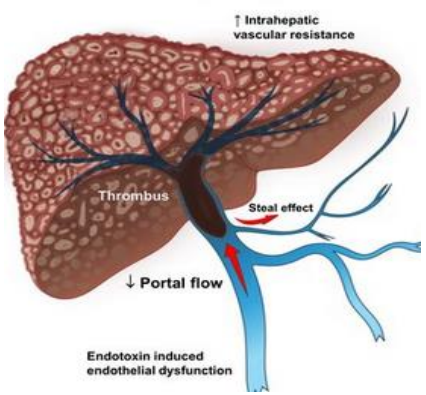

Gastroenterology 2025;168:396–404
J. Clin. Med. 2024, 13, 1517

Recommended standardized terminology for PVT

Feature	Definition
Time course	
Recent	Portal vein thrombus presumed to be present for < 6 months
Chronic	Portal vein thrombus present or persistent for > 6 months
Percentage occlusion of main portal vein	
Completely occlusive	No persistent lumen
Partially occlusive	Clot obstructing > 50% of original vessel lumen
Minimally occlusive	Clot obstructing < 50% of original vessel lumen
Cavernous transformation	Gross porto-portal collaterals without original portal vein seen
Response to treatment or interval change	
Progressive	Thrombus increases in size or progresses to more complete occlusion
Stable	No appreciable change in size or occlusion
Regressive	Thrombus decreases in size or degree of occlusion

Points for Classification of Portal Vein Thrombosis

Type of Classification	Features
PVT site	Type 1: only trunk Type 2: only branch: 2A one branch and 2B both branches Type 3: trunk and branches
Portal venous system occlusion	OCCLUSIVE: no flow in PV lumen NON OCCLUSIVE: flow visible in PV lumen
Duration and presentation	RECENT: first time detected in previous patent PV, presence of hyperdense thrombus on imaging, absent or limited collateral circulation, dilated PV at the site of occlusion -asymptomatic -symptomatic CHRONIC: no hyperdense thrombus; previously diagnosed PVT on follow up, portal cavernoma -asymptomatic -symptomatic: portal hypertension

J. Clin. Med. 2024, 13, 1517

PVT grading

Grade I: Partial PVT wherein the thrombus occupies less than 50% of the diameter.

Grade II: The obstruction occupies greater than 50% of the vessel lumen with or without minimal extension into the superior mesenteric veins.

Grade III: Complete obstruction of the portal vein with extension into the proximal part of the superior mesenteric vein.

Grade IV: Complete thrombosis of the portal vein along with proximal and distal parts of the superior mesenteric veins.

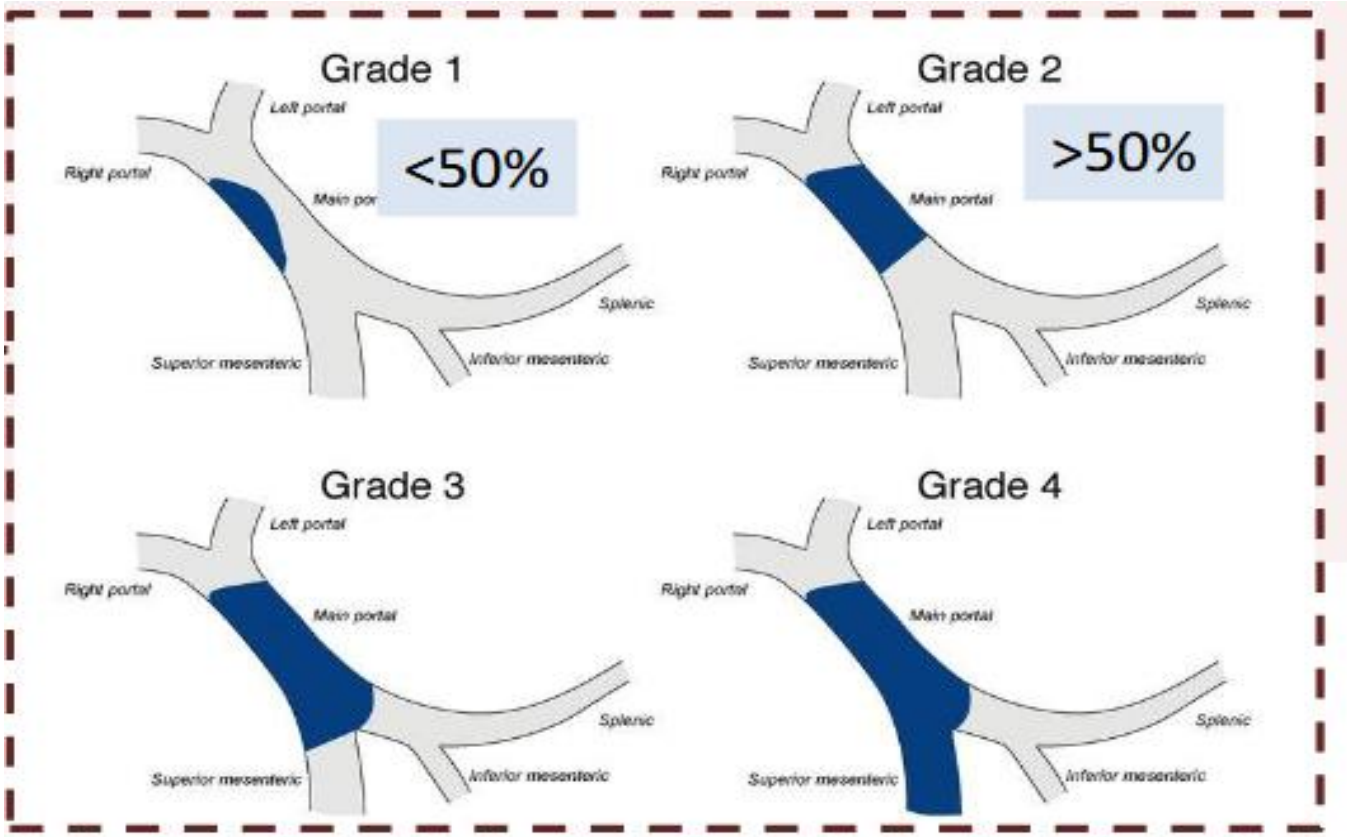

Yerdel Transplantation 2000

General Classification of PVT

A

Acute

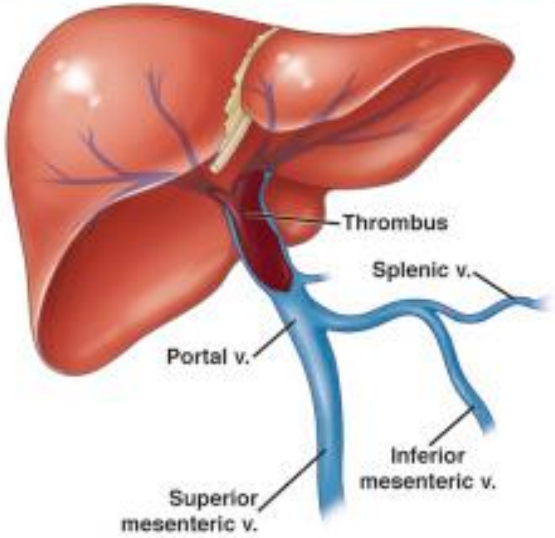

Non-cirrhotic

- Often presents with pain and treatment with anticoagulation is standard of care
- Commonly progresses to chronic cavernoma if left untreated

Cirrhotic

- Often found incidentally on imaging, but can present with symptoms
- Anticoagulation is indicated in certain situations (see text)
- Up to 40% may spontaneously recanalize with no therapy

Chronic

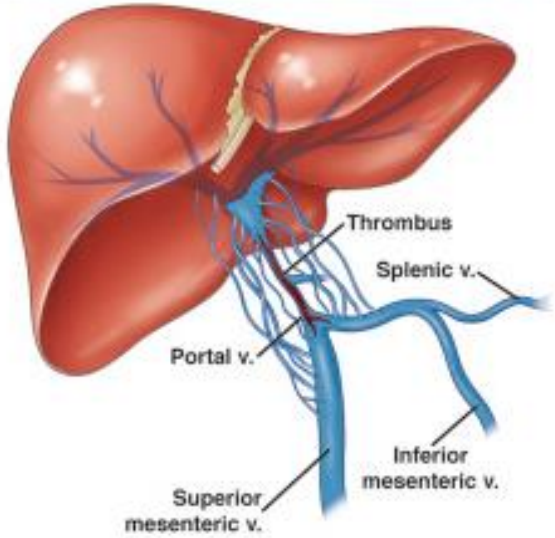

Non-cirrhotic

- Collateral circulation usually contains significant portoportal or mesoportal collateral veins
- Portal hypertension including bleeding gastroesophageal and ectopic varices can occur

Cirrhotic

- Collateral circulation dominated by portosystemic shunts
- If advanced especially with involvement of the confluence with superior mesenteric vein may complicate liver transplantation

B

Tumor related

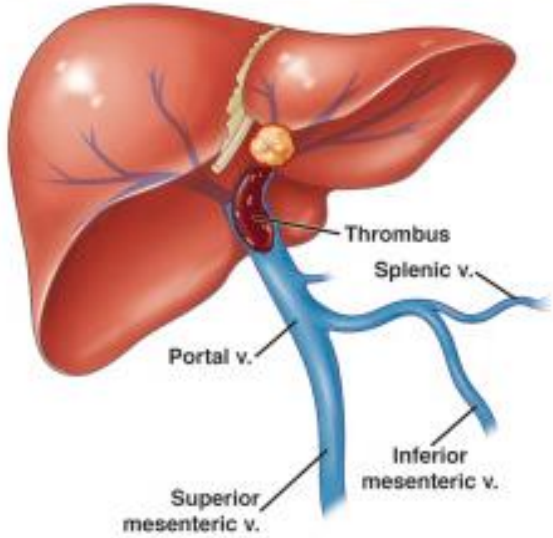

Malignant PVT

- Consideration of hepatocellular carcinoma is essential in cirrhosis
- Characteristic features on imaging include expanding thrombus with disruption of the vessel wall and arterial phase enhancement
- Distinguishing bland thrombus with uninvolved tumor is important in directing management
- Extrahepatic metastases should be considered as well in both non-cirrhotic and cirrhotic cases

Gastroenterology 2019;156:1582–1599

Acute vs. Chronic PVT:

Acute PVT

- Symptoms develop within 60 days of clot formation
- Better prognosis with early early treatment
- Higher chance of complete complete vein recanalization
- May present with sudden abdominal pain
- Liver function typically preserved

Chronic PVT

- Longstanding clot (>60 days)
- Development of portal cavernoma (collateral veins)
- Established portal hypertension
- Risk of variceal bleeding complications
- More challenging to treat effectively

The Pathophysiology of Portal Vein Thrombosis in Cirrhosis

Local Predisposing Factors

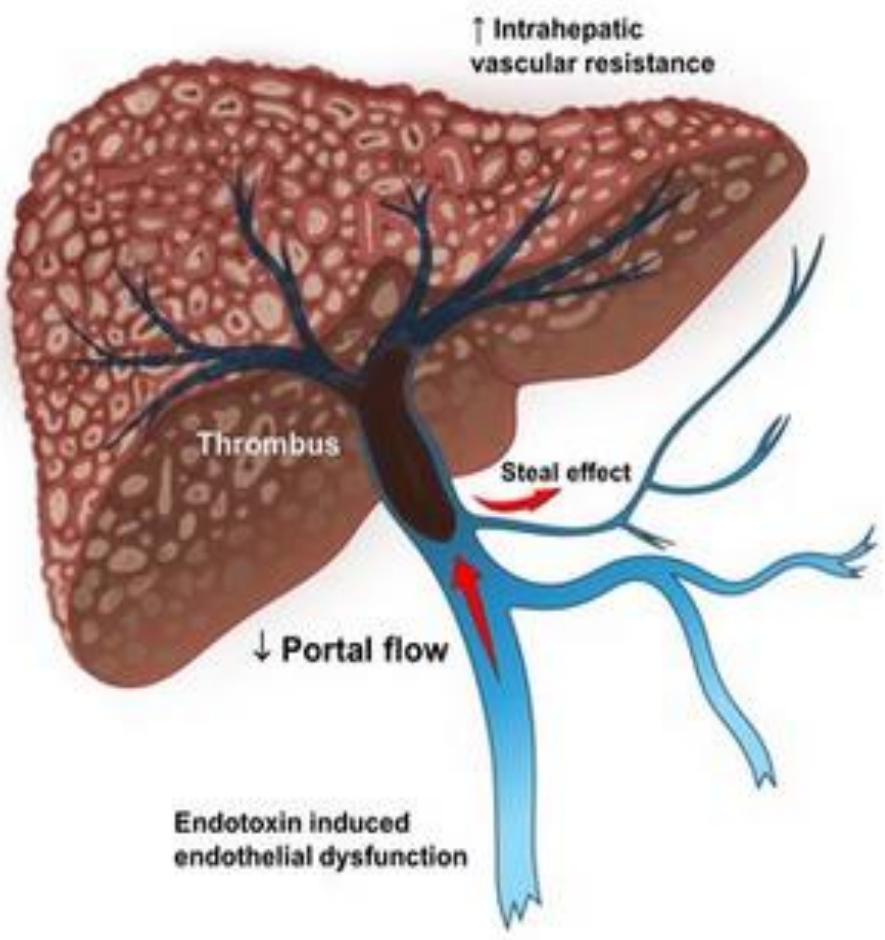

Systemic Predisposing Factors

Inherited thrombophilia

Prothrombin gene G20210A mutation

Factor V Leiden

JAK2 V617F mutation

Acquired thrombophilia in cirrhosis

ADAMTS13 deficiency

Increased Factor VIII

Protein C & S deficiency

Antithrombin deficiency

Increased fibrinolysis

Low platelet count

Coagulation factors deficiency



Other systemic risk factors

Hormonal therapy, malignancy, autoimmune disorders, etc.

Journal of Clinical and Translational Hepatology 2020;8(4):432-444

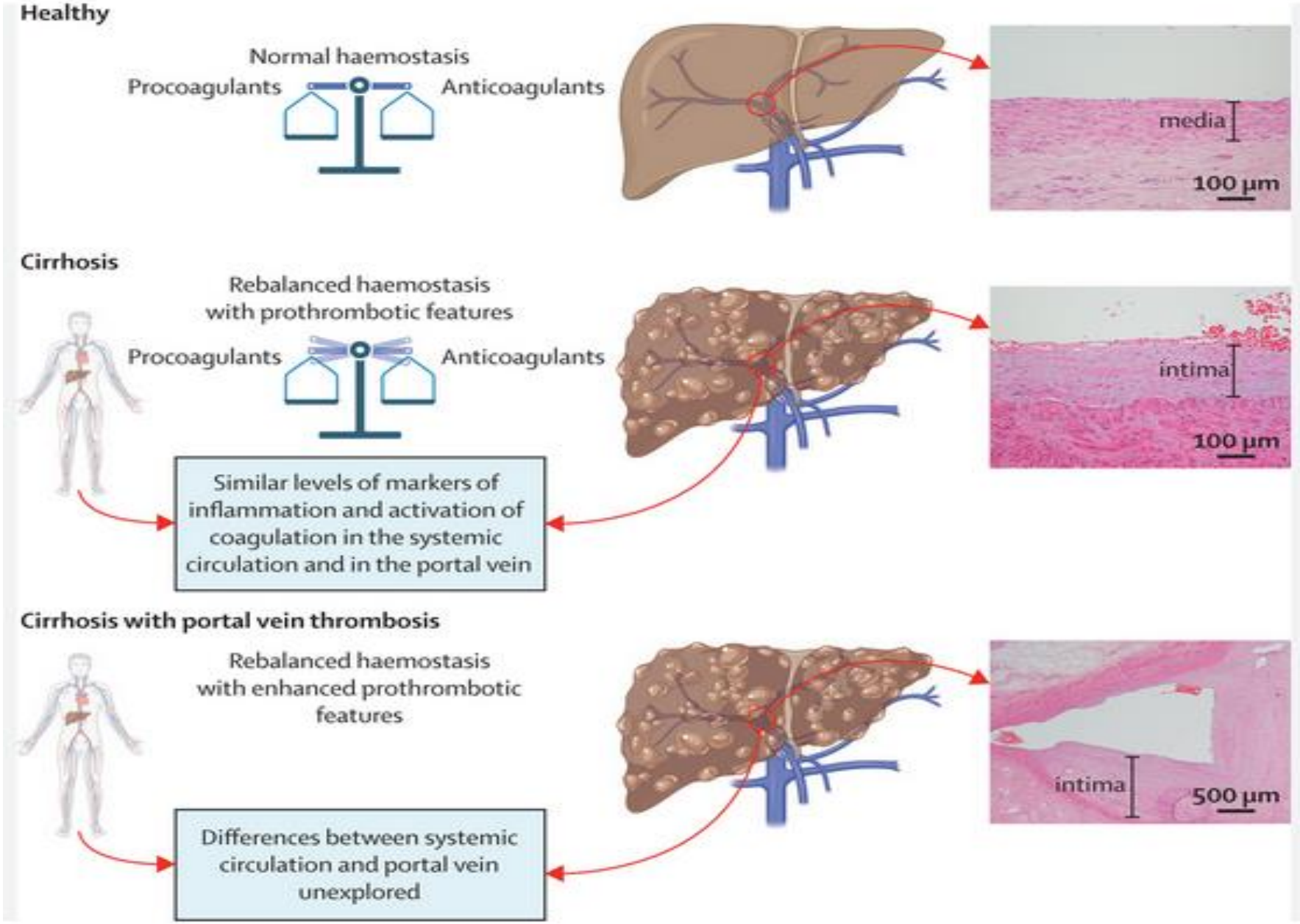

Lancet July 09, 2024



Risk factors for PVT

- prior variceal bleeding
- low platelet count
- decreased portal vein flow velocity
- Child-Pugh B-C stage
- pronounced portal hypertension
- decompensated disease stage
- sepsis
- interventional treatments like
  - varices endoscopic therapy,
  - abdominal surgery,
  - injury to the portal venous system (e.g. surgical portosystemic shunting or TIPS)

Risk factors of PVT in cirrhotic patient

- **History of encephalopathy**
- **Increased spleen thickness**
- **NAFLD, MASLD**
- **Autoimmune disease**

Epidemiology of PVT I cirrhosis

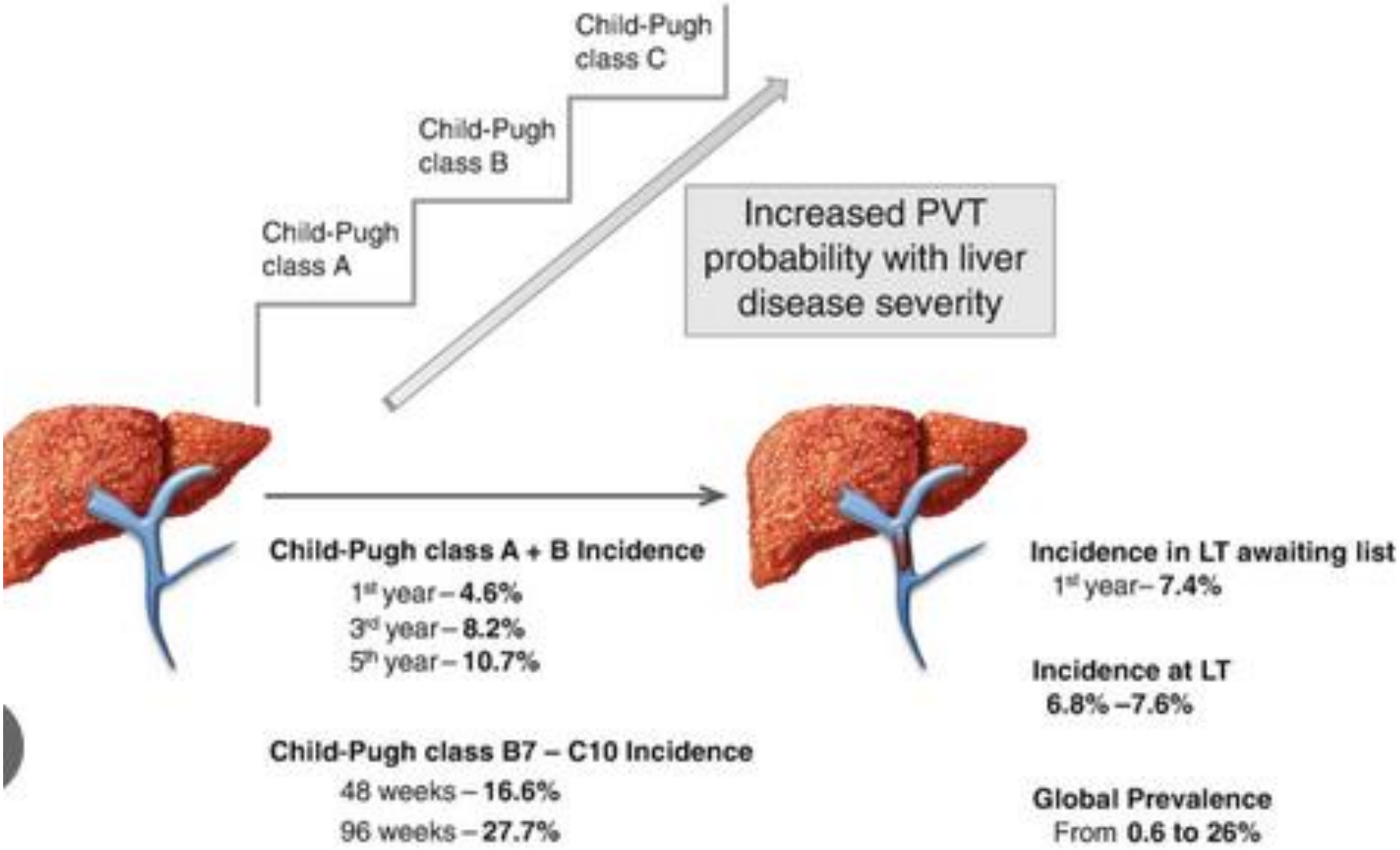

Nery, F.G. (2021). Epidemiology of Portal Vein Thrombosis.

Review > J Gastroenterol Hepatol. 2023 Oct;38(10):1710-1717. doi: 10.1111/jgh.16263. Epub 2023 Jun 24.

Natural history of portal vein thrombosis in cirrhosis: A systematic review with meta-analysis

Suprabhat Giri [1], Ankita Singh [2], Kailash Kolhe [3], Aditya Kale [2], Akash Shukla [2]

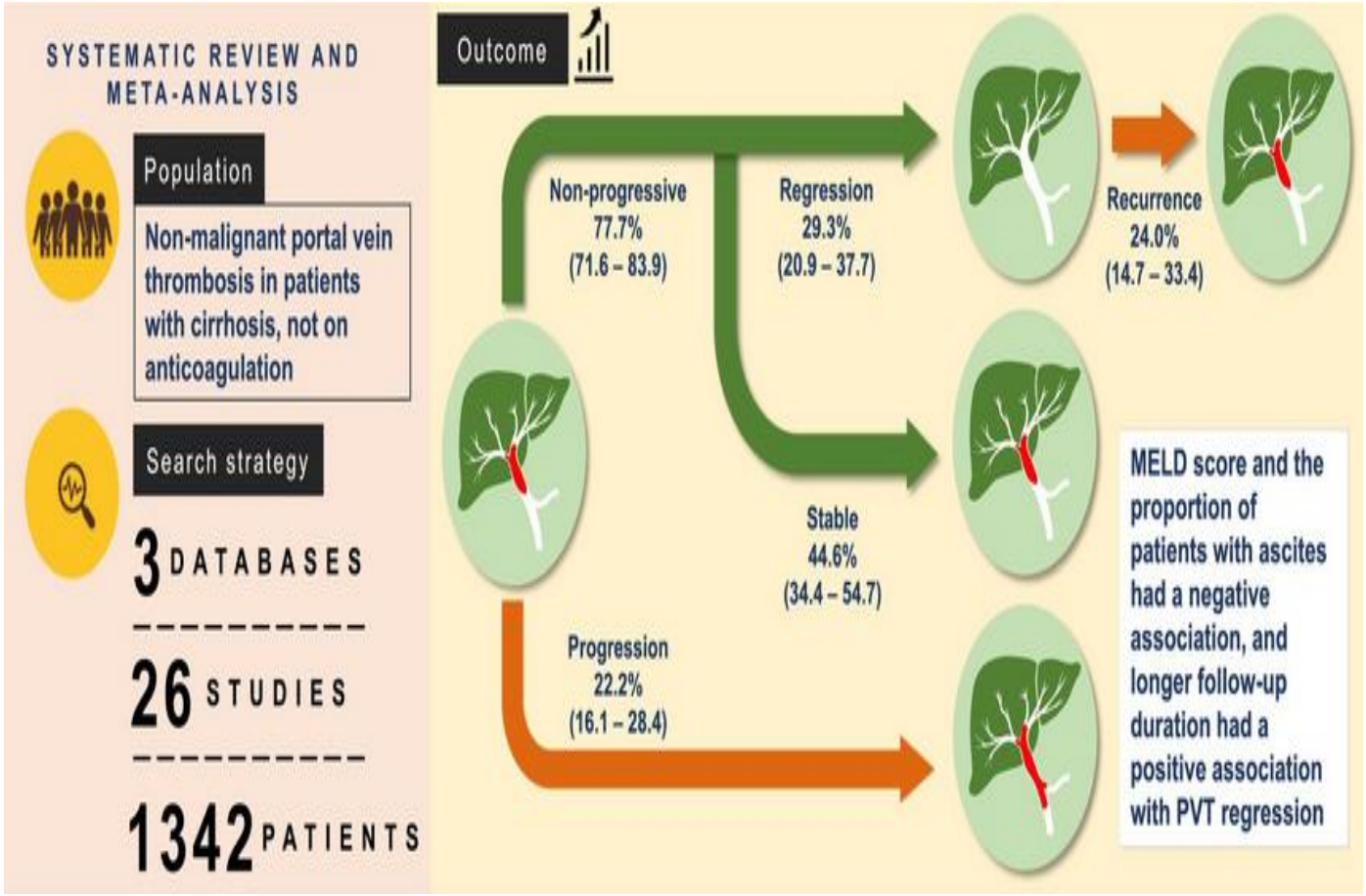

Conclusion:

Of cirrhotic cases
25% progressive,
30% improve, and
45% remain stable.

Screening of PVT in Cirrhosis

No Routine Screening

Asymptomatic patients with compensated cirrhosis do not require routine screening for PVT.

Confirm with Cross-Sectional Sectional Imaging

When PVT is identified on Doppler ultrasound,
confirm with CT or MRI to evaluate for malignancy and document clot extent, occlusion degree, and chronicity.

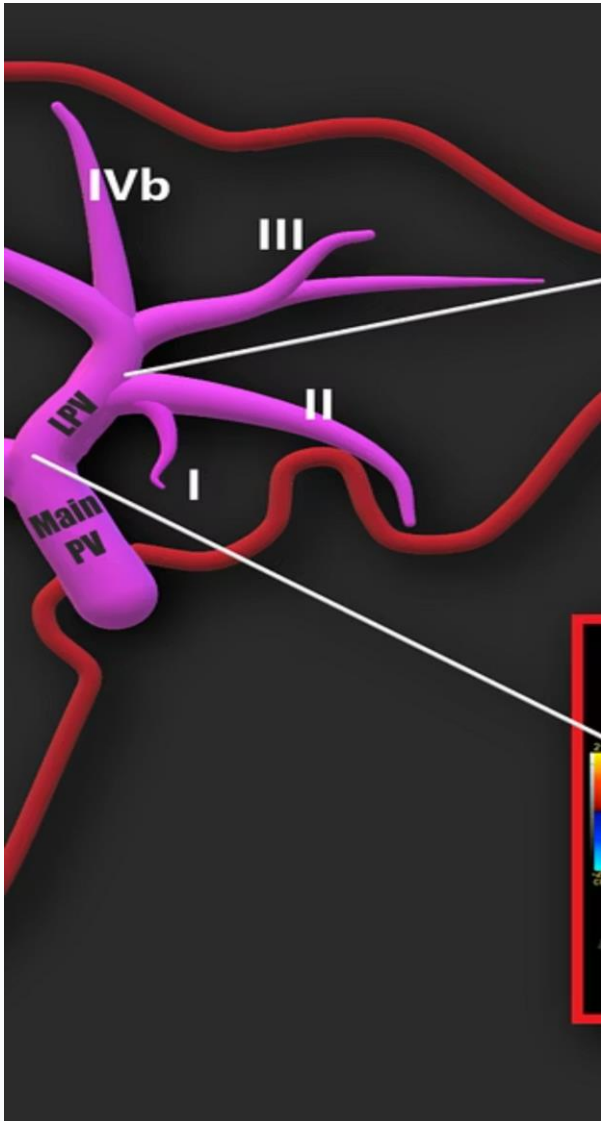

No Hypercoagulable Workup

Patients with cirrhosis and PVT do not require a hypercoagulable workup unless there are :
additional thromboemboli, suggestive lab abnormalities, or family history of thrombophilia.

AGA: Gastroenterology 2025;168:396–404

PVT complication

Intestinal Ischemia:

Intestinal ischemia is typically seen when acute PVT progresses to obstruction of the mesenteric venous outflow with reflex arterial constriction and occlusion.

Portal Hypertension:

Portal hypertension is responsible for most complications in patients with chronic PVT. It presents with splenomegaly, varices, or ascites. Portal vein thrombosis commonly forms varices in sites other than the esophagus and stomach (ectopic varices).

Septic Portal Vein Thrombosis:

Septic portal vein thrombosis (acute pylephlebitis) occurs when PVT develops in a patient with an abdominal focus of infection, such as appendicitis and diverticulitis

Portal Cholangiopathy :

Portal cholangiopathy is a complication that may develop with longstanding PVT due to extrinsic compression of large bile ducts from venous collaterals around the portal vein, may progress to ischemic strictures of bile ducts, presenting obstructive jaundice and cholangitis

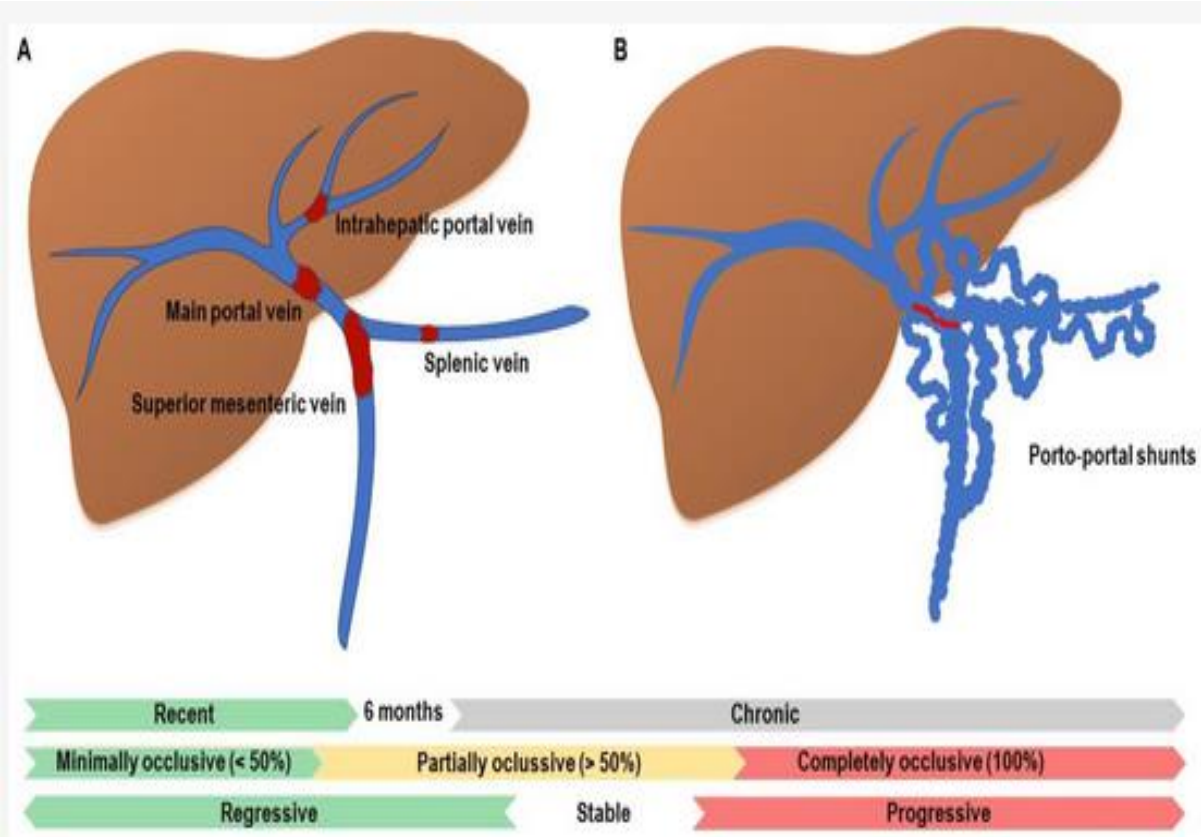

Cavernous transformation of the portal vein.

Atrophy of the MPV (marked in red) secondary to chronic PVT causes hypertrophy in the vasa vasorum of the portal vein with the apparition of porto-portal shunts.

J. Clin. Med. 2022, 11(21), 6435;

Portal Cholangiopathy/Biliopathy

Biliary tree abnormalities seen in patients with extrahepatic portal vein obstruction attributed to the compression by collateral vessels



- *Incidence (CPRE/Cholangio-MRI)* • 94% (81-100%)
- *Symptomatic: 19% (5-38%):* Abdominal pain; Jaundice; Cholangitis

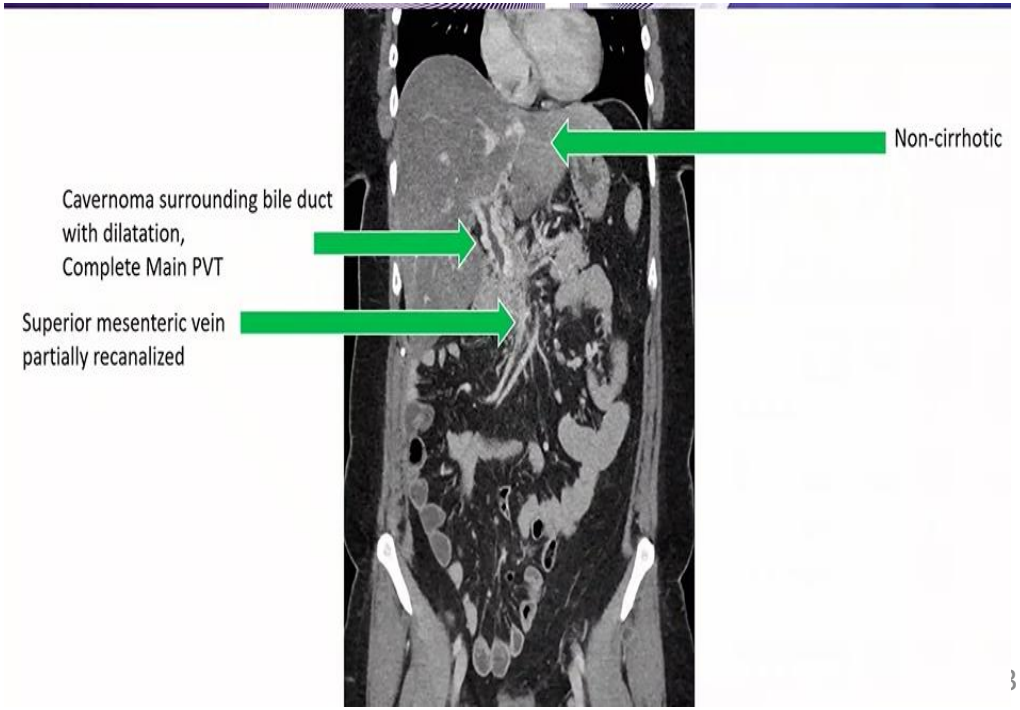

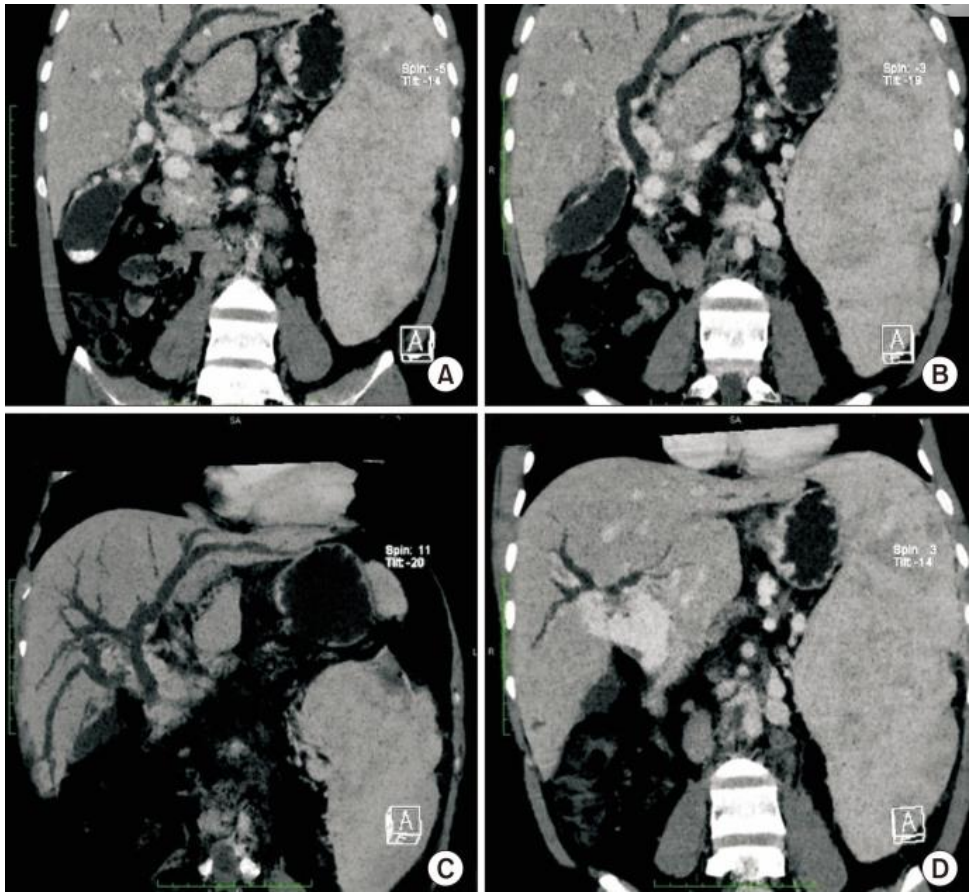

Contrast-enhanced CT of abdomen

(A, C) Showing portal cavernoma formation with compression over the lower common bile duct.
(B, D) Showing intra-hepatic biliary radicle dilatation.

Primary approach to PVT,
The main Question : Recent or Chronic



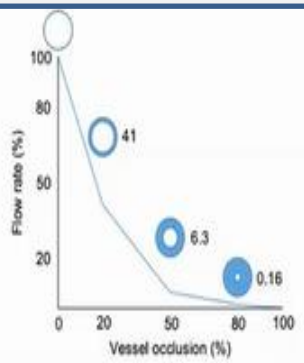

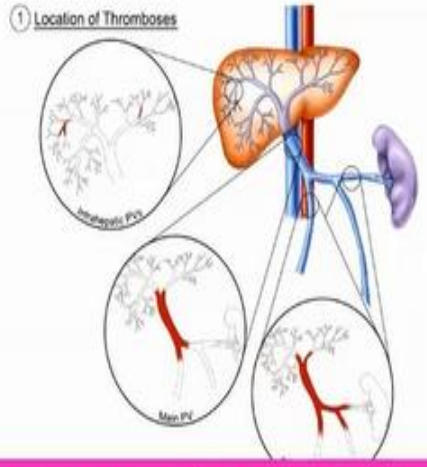



Not all SVT are the

In patients with recent PVT, perform a complete clinical evaluation including risk factors, liver morphology using imaging and liver stiffness measurement. EASL guidelines 2024





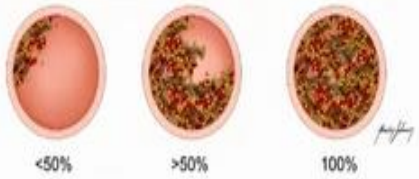



Portal cavernoma

Diagnosis of portal vein thrombosis (PVT)



Laboratory exams

- Nonspecific increase in D-dimer and inflammatory markers
- Generally normal liver function tests or a slight elevation in transaminases
- Limited specificity



Ultrasound

- First-line diagnostic tool
- Useful to estimate presence and the direction of portal flow
- Easy, low-cost, and fast examination with good sensitivity
- Operator experience, obesity, and ascites may limit accuracy



Contrast-Enhanced Ultrasound (CEUS)

- Noninvasive, cost-effective, safe for impaired renal function
- Superior in detecting small portal thrombi than CT
- Distinguishes malignancies based on arterial hyperenhancement
- Operator-dependent; affected by patient characteristics
- Cirrhotic liver abnormalities may reduce diagnostic accuracy



Computed Tomography (CT)

- Useful for uncertain diagnosis or suspected thrombus extension
- Precise view of mesenteric axis
- Risk of radiation and contrast-induced nephropathy
- Preferred over ultrasound for chronic PVT



Magnetic Resonance Imaging (MRI)

- High sensitivity without radiation exposure
- Longer acquisition times. high costs, limitations with intracorporeal devices, risk of motion artifacts



Ultrasonography

Ultrasonography and **doppler ultrasonography** are typically **first-line** imaging modalities to evaluate for PVT in cirrhosis

Doppler ultrasonography having greater than **75% sensitivity**

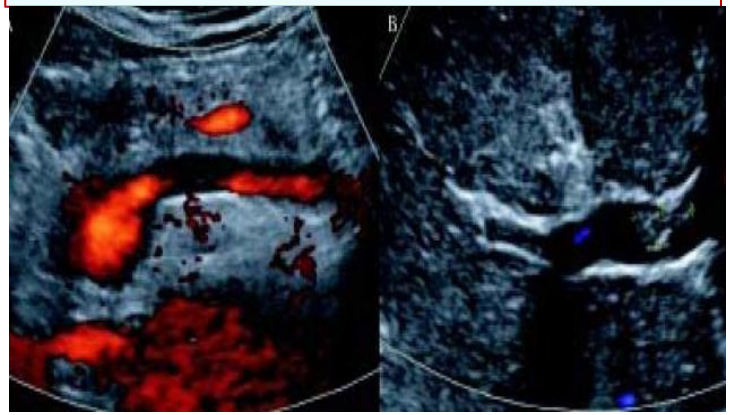

- ✓ **acute thrombus** : heterogenous material in the vessel lumen although it can also be hypoechoic or isoechoic .
- ✓ **chronic thrombus** will show increased hyper-echogenicity due to fibrinous composition
- ✓ **Contrast enhanced ultrasonography (CEUS)**

CEUS has a higher sensitivity (**91%**) and specificity (**100%**) of detection when compared to color doppler ultrasonography

Contrast Enhanced Ultrasound in PVT



standard US



PVT with enhancement in the arterial phase

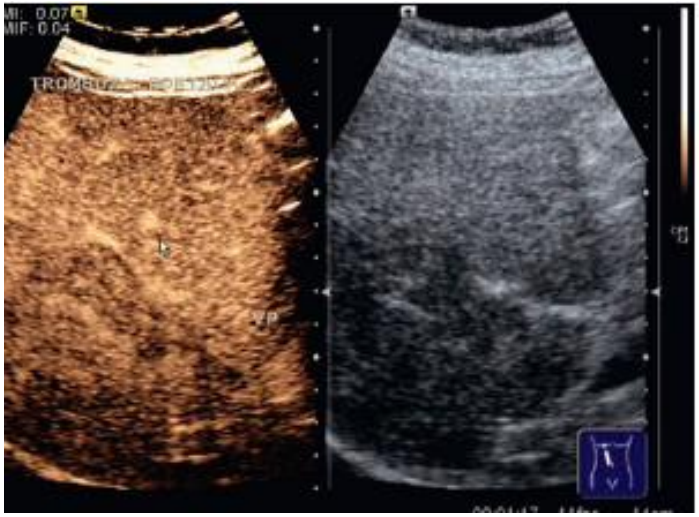

PVT with wash out in portal phase

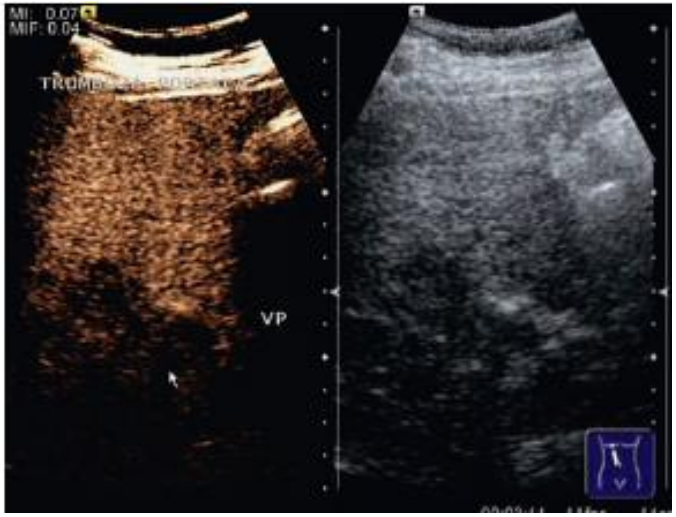

PVT with wash out in late phase

CT scan:

- **unenhanced CT**, fresh thrombi are typically hyperdense whereas the chronic thrombi can go undetected unless calcifications are present
- **contrast-enhanced CT** imaging, the lumen of the thrombosed vein does not enhance when compared to other vascular structures
- **Dual-energy multidetector CT** scan with iodine quantification has better results based on the iodine-uptake assessment

MRI

- MRIs, slow or stagnant flow secondary to thrombi will create a bright intraluminal signal
- Gadoxetic acid-enhanced MRI has superior sensitivity and specificity
- MR angiography has multiple advantages

Color Doppler US

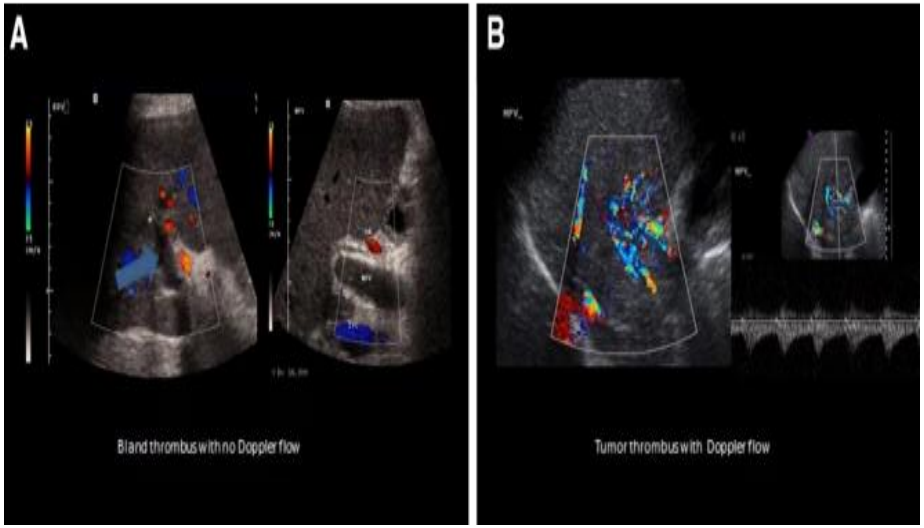

large bland thrombus

PV tumor thrombus that has arterial flow

IV-contrast-enhanced CT

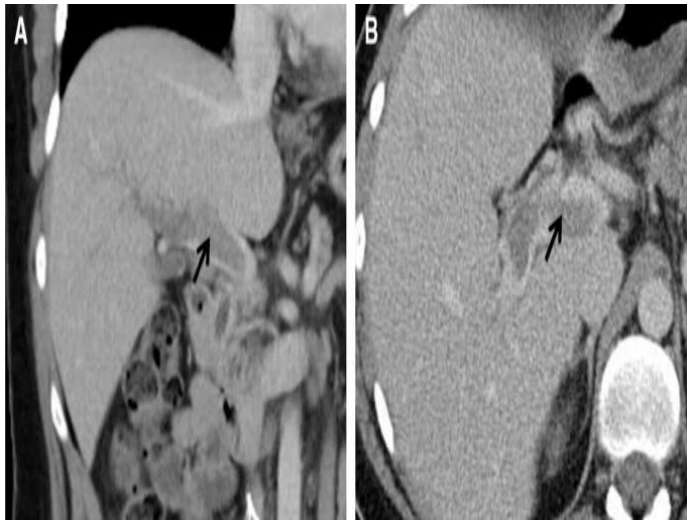

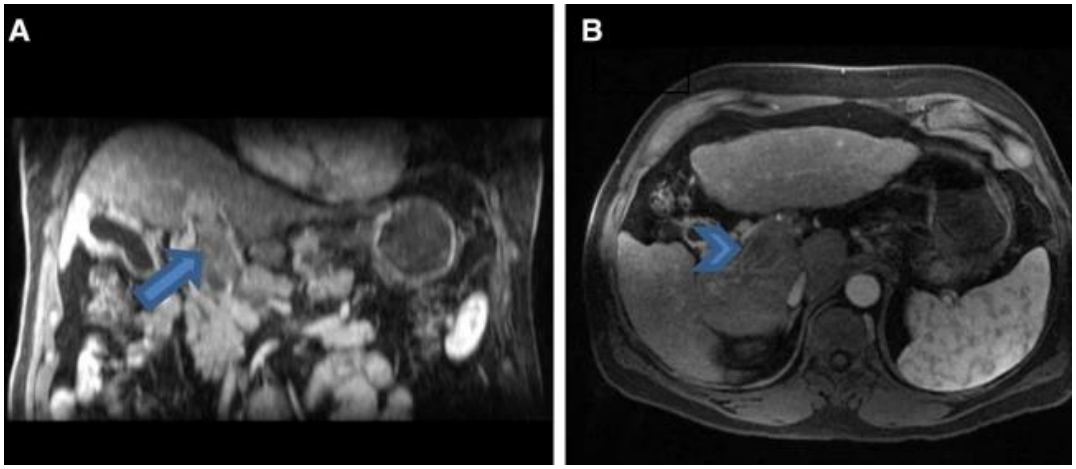

IV-contrast-enhanced MRI

Dual-Energy CT

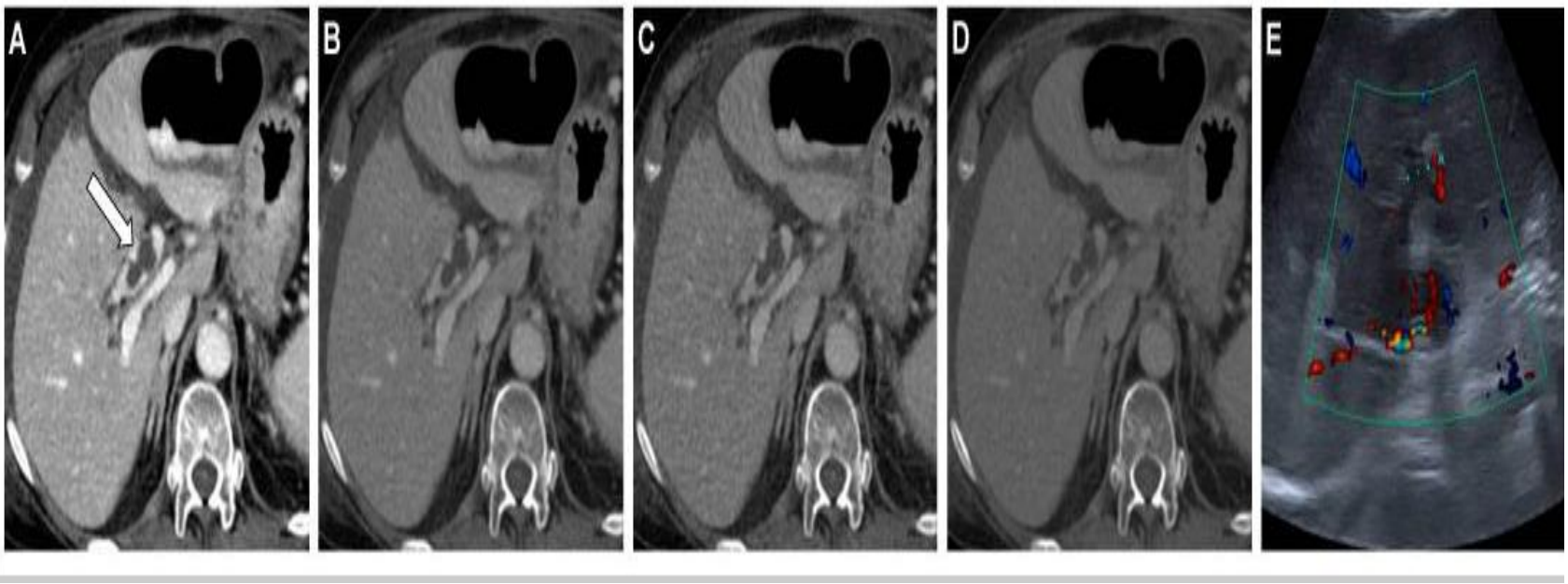

Axial DECT images of a woman with liver cirrhosis and portal vein thrombosis (arrow).

virtual monoenergetic imaging (VMI+) series at 40 keV (A) show higher vascular attenuation of the portal vein and a better delineation of the thrombus compared to 60 keV VMI+ (B), 60 keV VMI (C), and standard linearly blended M_0.6 images (D). On color duplex ultrasonography, some color signals are visible within the boundaries of the thrombus (E).

Pro-coagulant workup

investigation of prothrombotic disorders and local factors is recommended, including

- Antiphospholipid syndrome
- Protein C, S
- Antithrombin III levels
- Factor V Leiden mutation

Treatment strategy

What is the usual therapeutic modalities for PVT

Therapeutic strategies may differ according to underlying risk factors for thrombosis, may drive selection of different anticoagulant agents. Deciding the duration of anticoagulant treatment should take into account the transient or permanent nature of these risk factors

Treatment Strategies in general : Anticoagulation and Beyond



Anticoagulation

Early treatment improves 5-year survival to **85%**, preventing clot extension and promoting recanalization.



Thrombolytic Therapy

Direct clot-dissolving agents used in acute, severe cases cases when benefits outweigh bleeding risks.



Interventional Procedures

Transjugular approaches and catheter-directed treatments treatments are increasingly preferred over open surgery. surgery.



Underlying Cause Management

Treating cirrhosis, infection, or malignancy is essential for essential for long-term success.

What is the usual therapeutic modalities for PVT

The main and essential objective of the treatment is to limit clot extension and to provide the optimal environment for clot recanalization

Anticoagulant: There is a clear recommendation for using anticoagulation in non-cirrhotic acute PVT
The treatment aims to reverse or prevent the advancement of thrombosis and to treat complications of established PVT

Thrombolytic therapy in recent non-cirrhotic portal vein thrombosis can be done via indirect intra-arterial infusion of tissue plasminogen activator, urokinase , or streptokinase into the SMA or directly via the catheter introduced into a portal vein either transhepatically or through the transjugular approach

Thrombectomy: Surgical thrombectomy or mechanical thrombectomy by percutaneous transhepatic route is associated with the recurrence of thrombosis from intimal or vascular trauma to the portal vein

Transvenous intrahepatic portosystemic shunt(**TIPS**) placement

Considerations	Anticoagulant					
	Low molecular weight heparin	Vitamin K antagonist	Apixaban	Dabigatran	Edoxaban	Rivaroxaban
Standard dose	Parenteral. Weight-based dosing	Dosed according to INR. Usual target 2-3	10 mg daily for 7 d then 5 mg twice daily	150 mg twice daily after 5 d parenteral antico-agulant	60 mg once daily after 5 d parenteral antico-agulant	15 mg twice daily for 21 d then 20 mg once daily
Age	-	-	-	75-79 years reduce dose to 110-150 mg twice daily. ≥ 80 years reduce dose to 110 mg twice daily	-	-
Weight	Weight-based dosing	-	-	-	< 61 kg reduce dose to 30 mg once daily	-
Renal impairment	Use with caution if CrCl < 30 mL/min. Avoid enoxaparin if CrCl < 15 mL/min	-	Avoid if CrCl < 15 mL/min. Use with caution if CrCl 15-29 mL/min	Avoid if CrCl < 30 mL/min. Consider dose reduction to 110-150 mg twice daily if CrCl 30-50 mL/min	Avoid if CrCl < 15 mL/min. Reduce dose to 30 mg once daily if CrCl 15-50 mL/min	Avoid if CrCl < 15 mL/min. Consider dose reduction to 15 mg daily if CrCl 15-49 mL/min
Pregnancy	Safe	Avoid (especially 1st/ 3rd trimester)	Avoid	Avoid	Avoid	Avoid
Breastfeeding	Safe	Safe	Avoid	Avoid	Avoid	Avoid
Reversal agent	Protamine sulphate (partially effective)	Vitamin K, prothrombin complex concentrate	Andexanet alfa	Idarucizumab	None	Andexanet alfa
Other		Multiple drug and food interactions	DOAC contraindicated in anti-phospholipid syndrome			

LMWH is recommended In **pregnant** patients as the anticoagulant of **choice** during pregnancy.
VKA or LMWH are recommended in **breastfeeding** patients
DOAC should be **avoided** in pregnancy and breast feeding and Cr clearance <30 ml/min
DOAC is not recommended in anti-phospholipid syndrome

World J Hepatol 2024 May 27; 16(5): 751-765

Anticoagulation in chronic PVT without cirrhosis

Major and permanent prothrombotic risk factor?

Active cancer
Myeloproliferative neoplasm
Homozygous factor II or V mutation
Antiphospholipid syndrome
Paroxysmal nocturnal hemoglobinuria
Behcet disease

No

"Anticoagulation can be considered to prevent thrombosis recurrence"

Extension of thrombosis and levels of Factor VIII or of D-dimers may help

Yes

"Long term anticoagulation recommended"

DOAC might be preferred over VKA to facilitate adherence and improve safety

Chronic portal vein thrombosis without cirrhosis

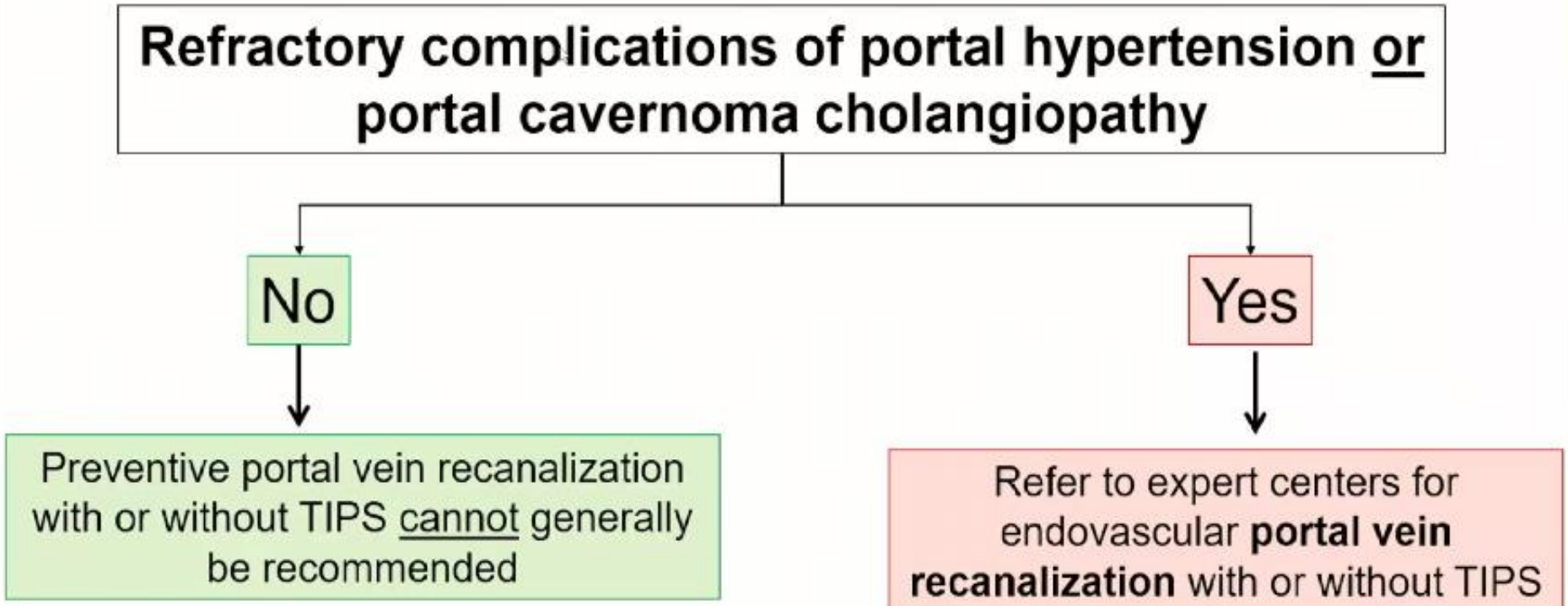

Chronic portal vein thrombosis without cirrhosis

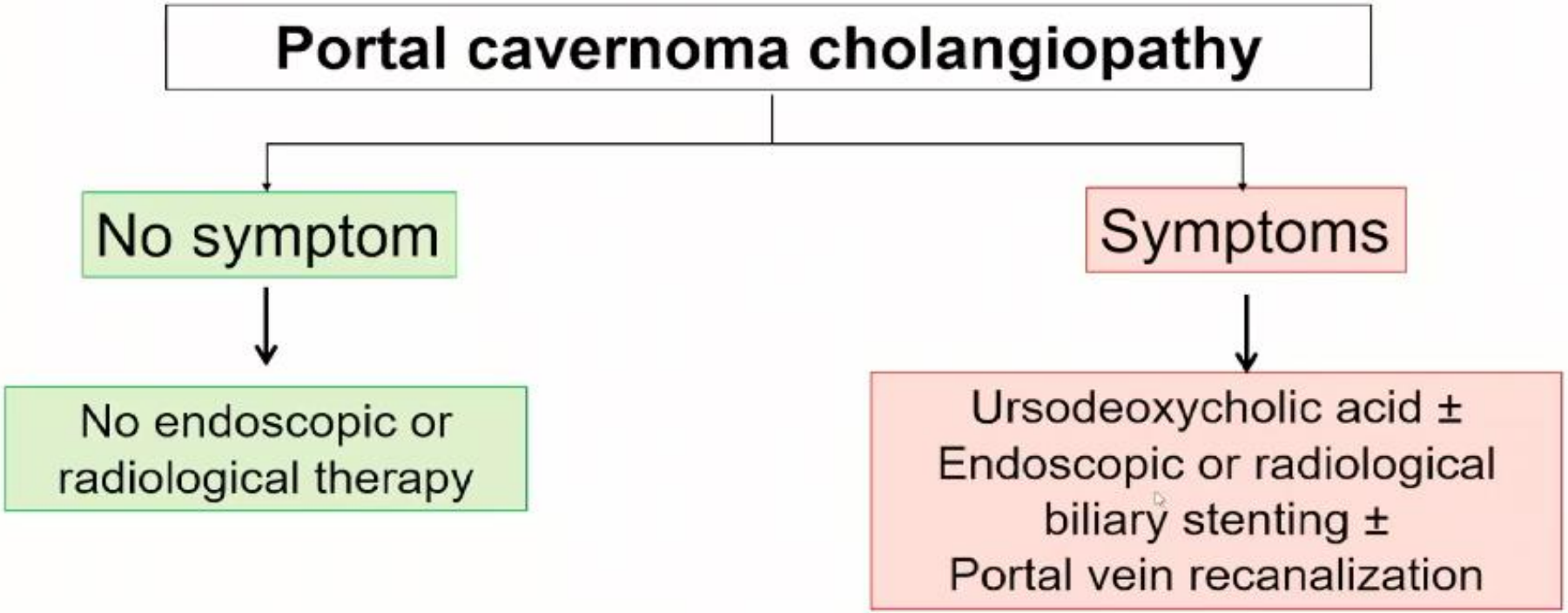

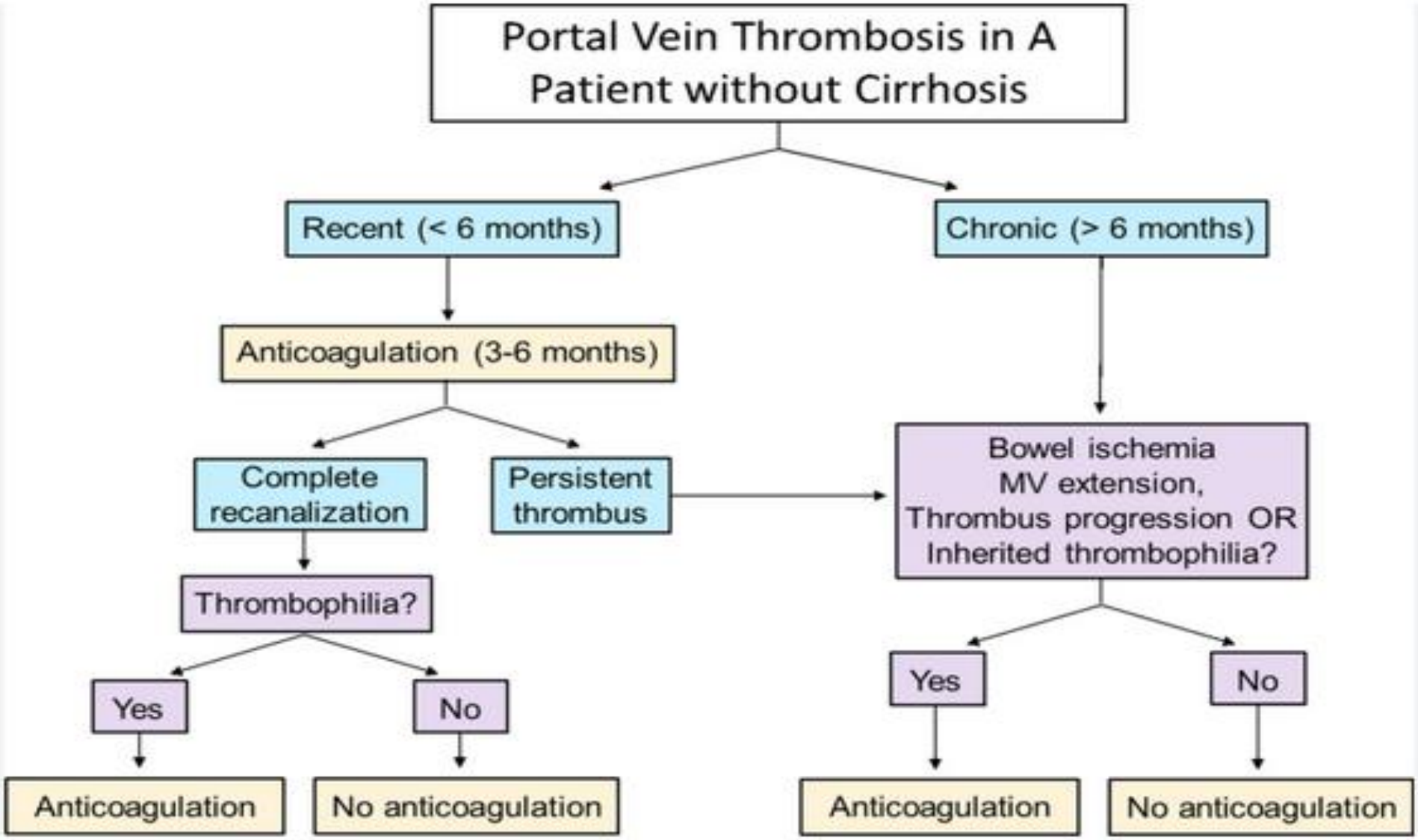

Curr Hepatology Rep 22, 244–251 (2023).

Portal vein thrombosis (PVT) with cirrhosis

screening / 6 mo

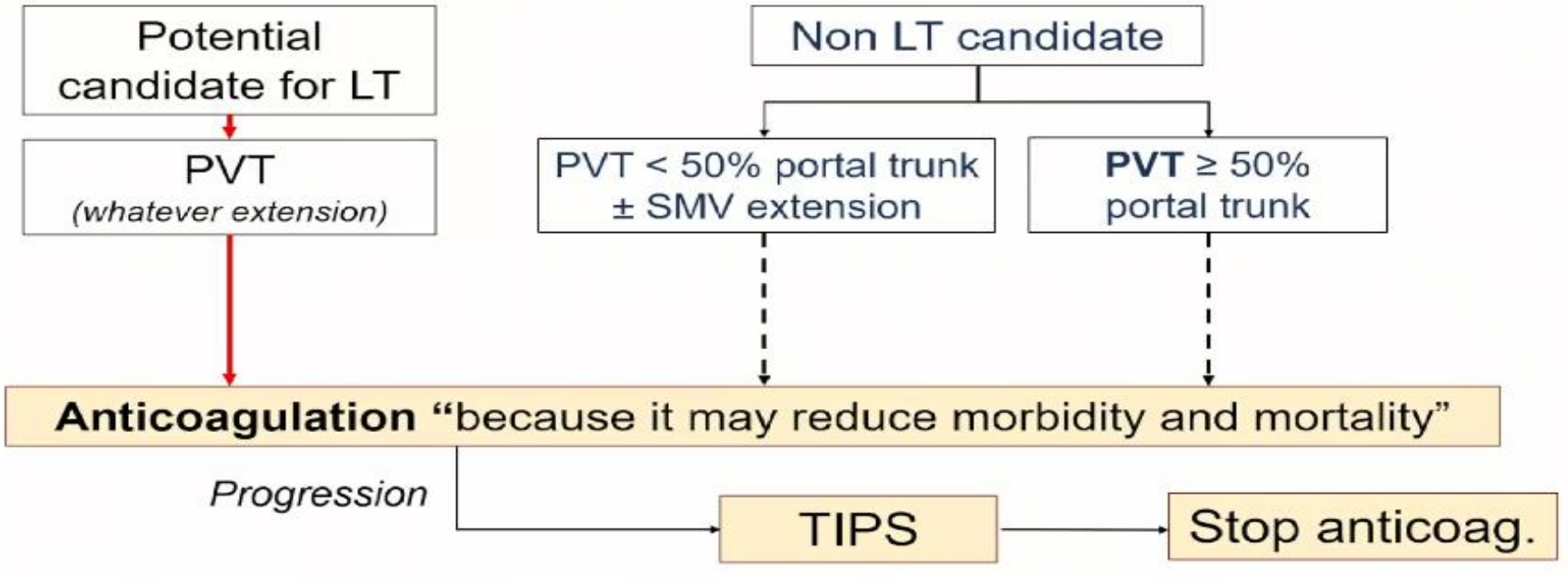

STEPWISE TREATMENT STRATEGY OF PVT IN LIVER CIRRHOSIS

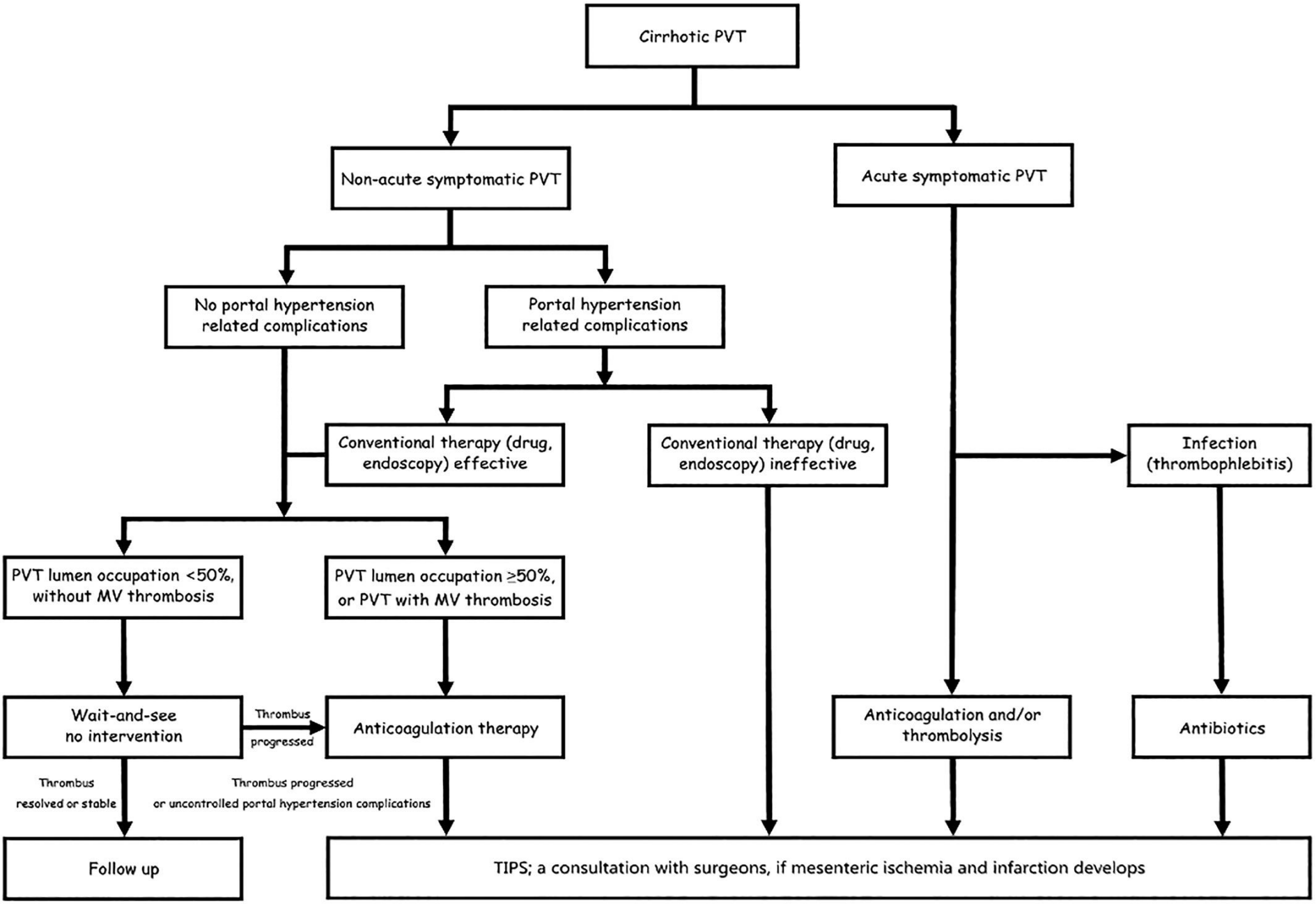

J of Digest Diseases, Volume: 22, Issue: 4, Pages: 176-186, First published: 20 January 2021, DOI: (10.1111/1751-2980.12970)

Anticoagulation Duration

Anticoagulant therapy is generally recommended for at least *3-6* months.

The continuation of anticoagulation is advised until recanalization or lifelong if the patient has an underlying permanent pro-coagulant condition or if there is thrombosis extending to the mesenteric veins

- **Be aware:**
- **Anticoagulation can increase the risk of bleeding.**
- **Acute PVT without cirrhosis have showed bleeding rates ranging from 0 to 6%**

J. Clin. Med. 2024, 13, 1517 ; JHEP Reports 2023 vol. 5 j 100667

Rational for permanent anticoagulation in major thrombotic factor and in idiopathic PVT

MPN cohorts

- Recurrent thrombosis incidence rate of 4.2 per 100 pt-years
  - With VKA :3.9 per 100 pt-years

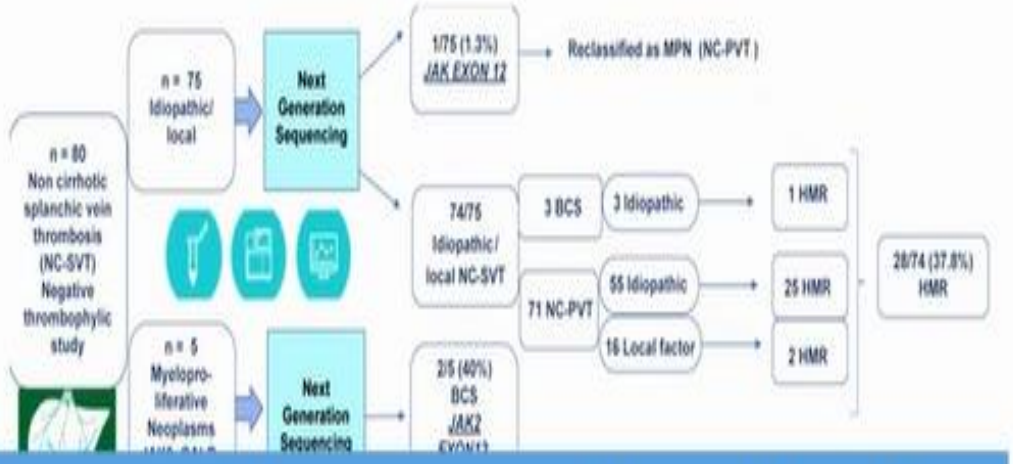

Risk factors for recurrence: Male sex, solid cancer, myeloproliferative neoplasms, Thrombophilia , idiopathic PVT:
HMR variant on NGS, fVIII>150

Urgent Cases: Intestinal Ischemia

Urgent Anticoagulation Required

These patients should be managed by a multidisciplinary team when available, including: including:

- Gastroenterology and hepatology
- Hematology
- Interventional radiology
- Surgery

AGA: Gastroenterology 2025;168:396–404

When to Consider Observation of PVT

No intestinal ischemia and recent thrombosis (<6 months) involving only the intrahepatic portal vein branches or <50% occlusion

follow-up imaging every 3 months is required,
and anticoagulation should be started if:

- **Symptoms develop**
- **Patient becomes a liver transplant candidate**
- **Clot progression occurs**

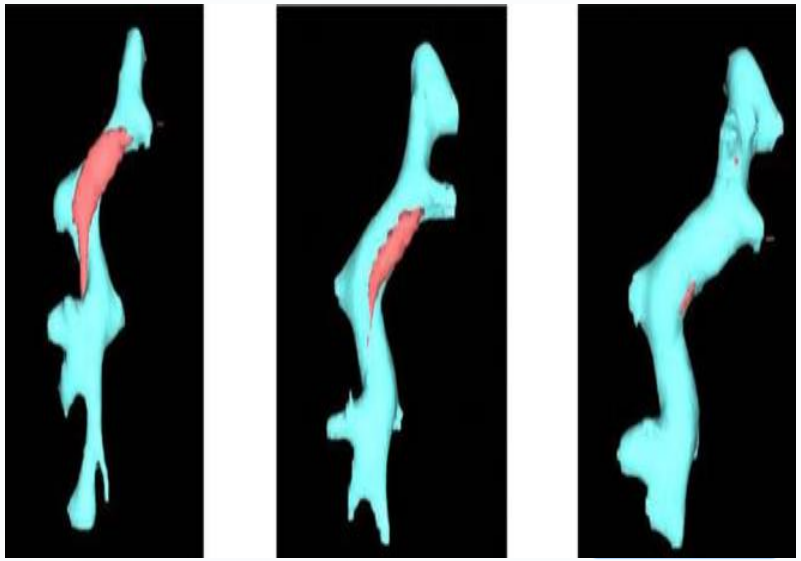

AGA: Gastroenterology 2025;168:396–404

When to Avoid Anticoagulation

Chronic PVT

Anticoagulation is not advised for patients
with Cirrhosis
with chronic (>six months) PVT
with complete occlusion
with collateralization (cavernous transformation).

These patients are very unlikely to recanalize with anticoagulation therapy.

AGA: Gastroenterology 2025;168:396–404

management of PVT in cirrhosis

PVT characterized on multiphase cross-sectional imaging

Intestinal ischemia

Inpatient care for urgent anticoagulation and multidisciplinary evaluation

Perform prophylaxis for variceal bleeding including band ligation* if high risk varices present and NSBB intolerant



Recent (< 6 months) thrombosis of intrahepatic branches or < 50% of main trunk, splenic vein, or mesenteric vein

Recent (< 6 months) thrombosis with 50%–100% occlusion of main PV or mesenteric veins

Complete, chronic (> 6 months) PVT with collateralization

Symptomatic or transplant candidate

Consider observation with serial cross-sectional imaging every 3 months

Clot progression

Consider timely AC

No anticoagulation, unlikely to recanalize

Patients with largest potential AC benefits:

- Awaiting liver transplant
- Progressive thrombus
- Additional hypercoagulable state (ie, inherited thrombophilia, MPN)



AGA: Gastroenterology 2025;168:396–404

Choice of anticoagulation agent

- ✓ Low molecular weight heparin (**LMWH**) and direct oral anticoagulants (**DOACS**) are considered **safe** in patients with **cirrhosis** and PVT.

- ✓ The drug selection needs to be individualized and adverse effects need to be discussed with the patient.

- ✓ **Warfarin** therapy has a narrow therapeutic window and the baseline elevation of the PT (prothrombin time) and INR in these patients creates difficulty for monitoring and dosing.

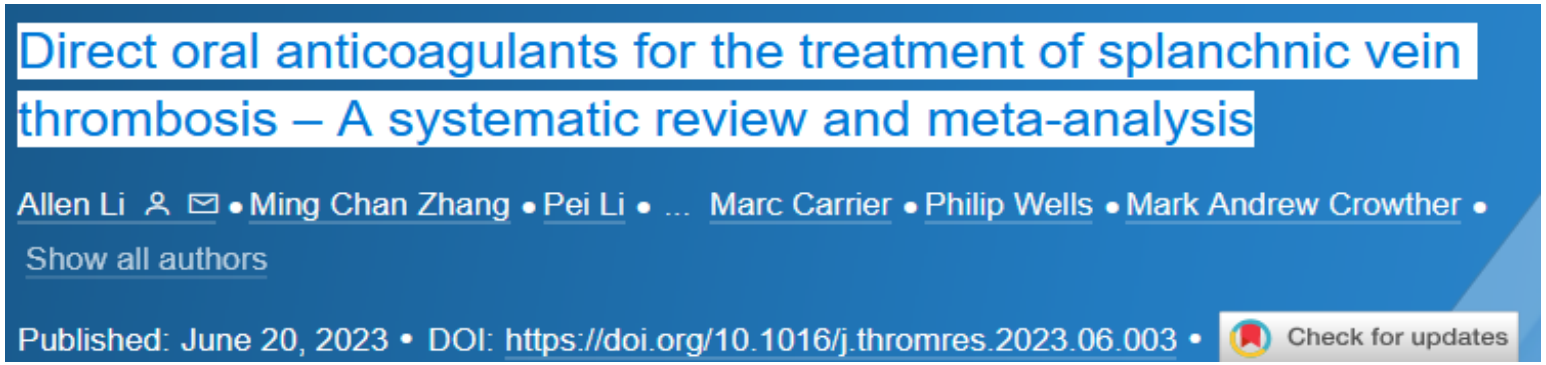

DOACs were more effective than **VKAs** (OR = 4.33; 95 % CI: 2.4, 7.83) in **non-cirrhotic patients** and no anticoagulation in cirrhotic patients (OR = 3.86; 95 % CI: 1.49, 10.03).

DOACs had a statistically significant reduction in major bleeding compared to observation, LMWHs and VKAs in non-cirrhotic patients.

No difference in major bleeding was found between DOACs and observation, LMWH, or VKAs in cirrhotic patients.

Systematic Review and Meta-analysis



Non-cirrhotic patients
N=489

Cirrhotic patients
N=394



DOAC

*Apixaban n=34
Dabigatran n=62
Edoxaban n=20
Rivaroxaban n=144



VKA

Recanalization
Non-Cirrhotic patients: OR = 4.33; 95% CI: 2.4, 7.83
Cirrhotic patients: OR = 3.90; 95% CI: 0.96, 15.87
ISTH Bleeding
Non-Cirrhotic patients: OR = 0.12; 95% CI: 0.02, 0.69
Cirrhotic patients: OR = 0.46; 95% CI: 0.07, 3.20



LWMH

Recanalization
Non-Cirrhotic patients: OR = 1.43; 95% CI: 0.76, 2.71
Cirrhotic patients: OR = 2.03; 95% CI: 0.66, 6.22
ISTH Bleeding
Non-Cirrhotic patients: OR = 0.13; 95% CI: 0.03, 0.62
Cirrhotic patients: OR = 0.73; 95%CI: 0.17, 3.1

DOACs appear to be a favorable alternative to VKAs and LMWHs in non-cirrhotic patients.

J. Thromb Haemost. 2023, 22, 534–544

Choice of anticoagulation agent

DOACs Vs vitamin K antagonists (**VKA**) :

- the pooled rate of PVT **recanalization** among cirrhotic patients was **87.3%** versus **44.1%** respectively.
- DOACs were associated with an overall lower risk of major bleeding events when compared to VKAs but,
- have similar risks of variceal bleeding and death

DOACs and LMWH may be safer and more efficacious than warfarin

in patients with **cirrhosis** and **plat <50 long –time unfractionated heparin** should be **avoided** because of the high risk (up to 20%) of heparin-induced thrombocytopenia, especially in patients with MPNs

- Rivaroxaban is contraindicated in patients with Child Pugh Group B and C cirrhosis with potential to be hepatotoxic
- Apixaban has no warnings against its use in patients with Child Pugh Group A and B cirrhosis .
- Edoxaban has both hepatic and renal clearance whereas **dabigatran** has predominantly renal clearance

Front Med (Lausanne). 2023; 10: 1134801.

Anticoagulation by Cirrhosis Severity

Child-Pugh Class A/B

✓ All anticoagulant options can be considered:

- **Vitamin K antagonists**
- **Low-molecular-weight heparin**
- **Direct oral anticoagulants (DOACs)**

DOACs offer convenience as dosages are independent of INR monitoring.

Child-Pugh Class C

Only low-molecular-weight heparin should be should be used in patients with decompensated decompensated Child-Pugh class C cirrhosis. cirrhosis.

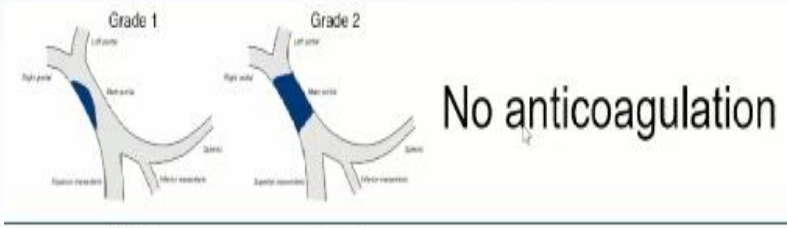

AGA: Gastroenterology 2025;168:396–404

Variceal Screening and Anticoagulation Options Options

Variceal Screening

Patients with cirrhosis and PVT warrant endoscopic variceal screening if not already on nonselective beta-blocker therapy.

Avoid delays in anticoagulation initiation as this decreases odds of portal vein recanalization.

Anticoagulation Options

- Vitamin K antagonists
- Low-molecular-weight heparin
- Direct oral anticoagulants

Decision should be individualized based on based on patient preference and Child-Child-Turcotte-Pugh class.

AGA: Gastroenterology 2025;168:396–404

Monitoring and Treatment Duration

Monitoring Response

Patients on anticoagulation for PVT should have cross-cross-sectional imaging every 3 months to assess response t response to treatment.

Treatment Duration

- **If clot regresses:** continue until transplantation or at least until clot resolution in non-transplant patients
- **If complete resolution**: continue if listed for transplant
- **If no response**: consider salvage procedures or treatment discontinuation

Key point
PVT increases the risk of acute variceal bleeding and recurrence of bleeding, Although
its impact on mortality has mostly been shown in the post-transplant setting.

AGA: Gastroenterology 2025;168:396–404

Made with GAMMA

Portal Vein Revascularization with TIPS

Consider TIPS for selected patients with cirrhosis and PVT who have:

Refractory Ascites

Patients with cirrhosis and PVT who have persistent ascites despite medical therapy may benefit from TIPS.

Variceal Bleeding

TIPS may be appropriate for those with history of variceal bleeding that is difficult to control with standard approaches.

Transplant Candidates

Portal vein revascularization with TIPS may be considered if recanalization can facilitate the technical feasibility of transplantation.

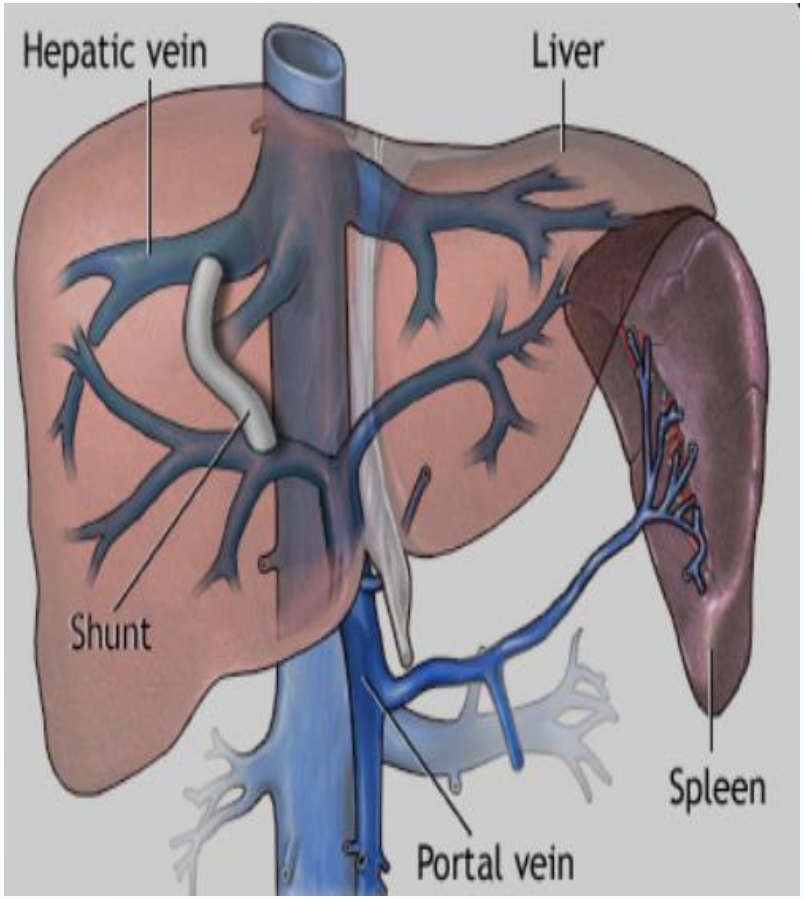

AGA: Gastroenterology 2025;168:396–404

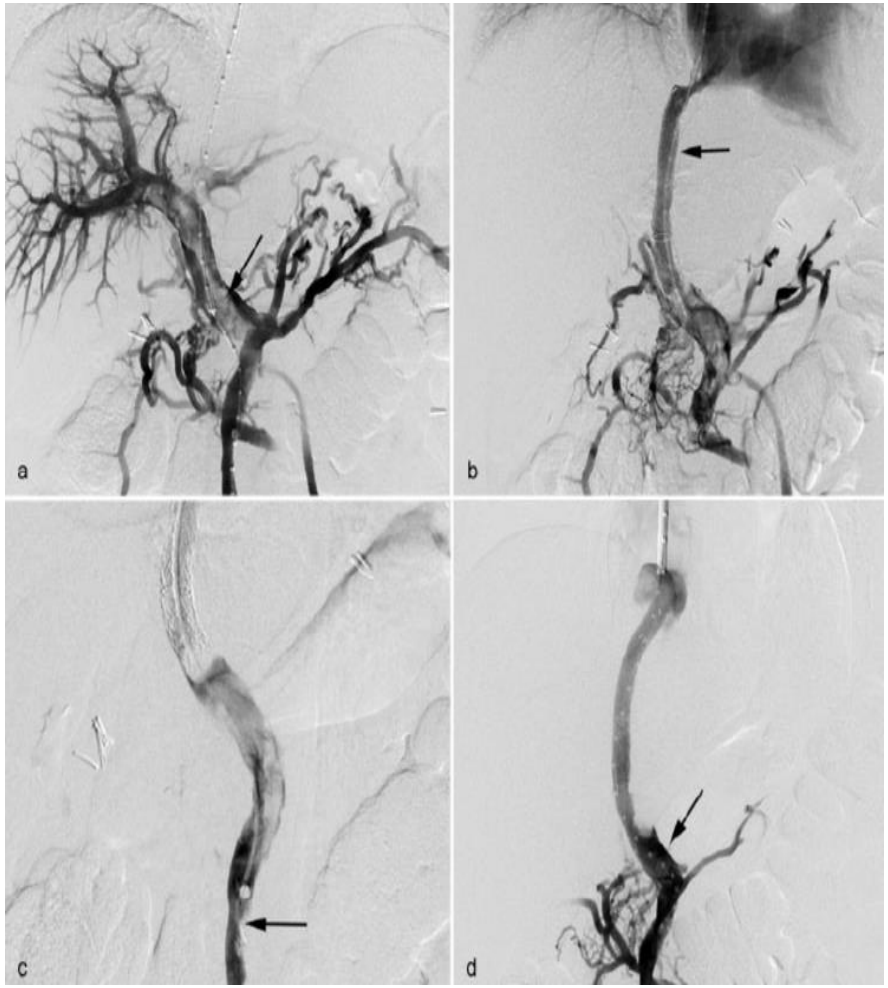

a: large PVT;
b: TIPS implementation;
c: mechanical thrombectomy;
portal vein with near complete patency, along with TIPS

New approach to Recanalization of PVT

Trans-splenic

Trans-mesenteric



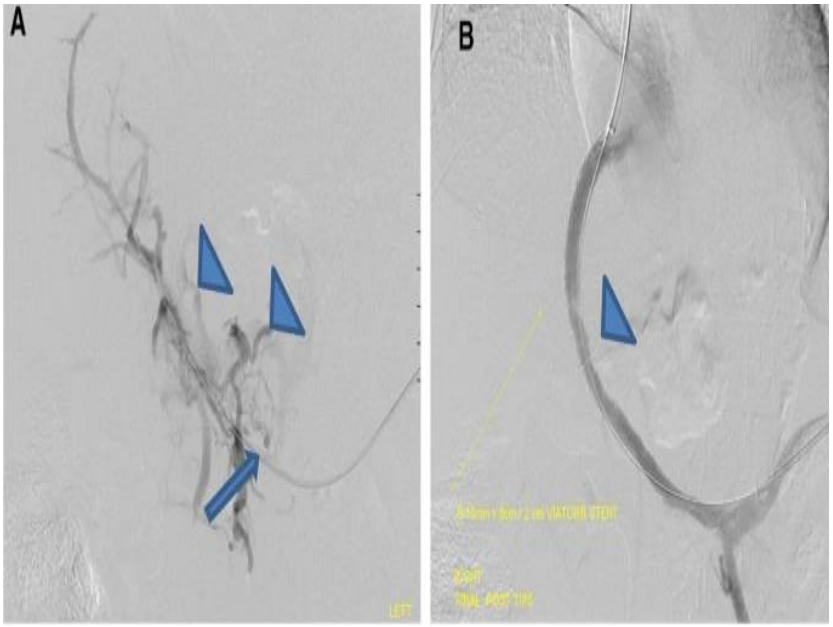

Portal vein access obtained via transsplenic puncture demonstrating complete chronic oblitrative portal vein occlusion (arrow) with cavernous transformation

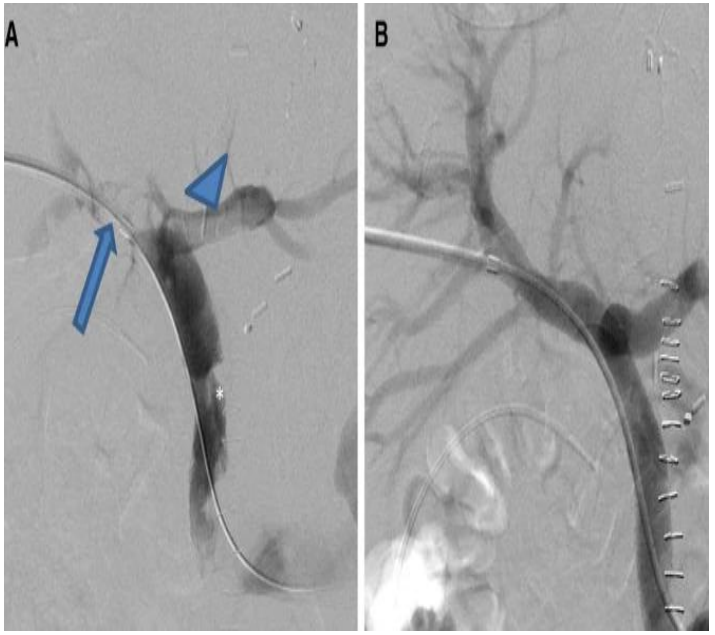

Portal vein access obtained via transhepatic puncture demonstrating complete right (arrow) and left (arrowhead) intrahepatic PVT with incomplete thrombosis of the SMV

Neoplastic PVT treatment in cirrhosis

Distinguishing benign from malignant PVT is critical:

Intra-thrombus vascularity, is a sign implying malignant PVT on both CT and MRI.

Blunt thrombi are avascular and will not enhance during contrast-enhanced ultrasound examination

Malignant PVT : a **hyperenhancement** pattern of the portal thrombus in the arterial phase, with **"wash out"** in the portal or late phase

Treatment :

SORAFENIB as the treatment of choice for cases involving vascular invasion

Also Chemoembolization or Resection , arterial infusion Chemotherapy, RFA

